

HEREDITARY SPHEROCYTOSIS

Dr. Syed Ahmad Murtaza

PG Trainee FMH

BIODATA

□ NAME	Shaneela Suri
□ Age	17
□ Gender	Female
□ Residence	Samanabad
□ D.O.A	03/11/08
□ M.O.A	Emergency

Chief complaints

- Off and On yellowish discolouration of skin and sclera.....since birth
- Of and on Pallor.....since birth
- Fever5 days

HOPI

- My patient history dates back when since after birth she was noticed to have multiple episodes of yellowish discolouration of skin and sclera.
- Associated with intermittent pallor ,weakness, fatigue and shortness of breath on exertion.
- There is also history heaviness in left hypochondrium.

HOPI

- Yellowish discolouration of skin and sclera during episodes is not associated history of drug intake, low grade fever, anorexia, nausea, vomiting, bleeding, weight loss, pain in RHC, pruritis and clay colored stool.

HOPI

- There is h/o fever, high grade, intermittent, chills and rigors, headache, malaise, nausea retro- orbital pain & rash over the body from last 5 days.
- Fever was not associated with neck stiffness, altered sensoriom, ear & eye discharge, productive cough, diarrhea, burning micturation or any ulcer in body

Past history

- H/O blood transfusions 6 times since childhood
- No history of any drug intake or surgical procedure

Family history

- H/O hematological disorder in paternal family with normal life expectancy.
- H/O splenectomy in paternal family
- No h/o Hypertension ,DM,IHD,CVA,COPD, Asthma and T.B.

Personal history



- Non-smoker, non-alcoholic, student with normal bowel and bladder habits

Menstrual history

- Age of menarche 13 years
- No h/o irregular menstruation, menorrhagia

Immunization History



- Immunized against communicable diseases according to EPI schedule

Allergic history



- Not significant for any allergy

Examination

- Young female well oriented in time, space and person with following vitals
- Pulse 112/min
- B/P 100/70
- Temp: 102 F
- Pallor jaundice positive
- purpuric skin rash positive
- No clubbing,cyanosis,edema,thyroid,LN

Examintaion

- GIT Splenomegaly 3 finger below
 costal margins
- Chest Normal vesicular breathing
- CVS S1+S2+0
- CNS grossly intact

Provisional diagnosis

- Hemolytic anemia
 - Hereditary spherocytosis
 - Thalassaemia
 - G-6-P-D deficiency anemia

- Dengue fever
 - malaria
 - enteric fever

Investigation

□ Hb	6.7
□ MCV	78
□ MCHC	35
□ WBC	1.1
□ Neutrophils	60%
□ Lymphocytes	35%
□ PLT	85

Investigation

□ LFTS:

STB : 2.7

Indirect: 1.9

direct: 0.8

SGPT: 92

SGOT: 137

Alk. Phos: 350

- LDH: 1736
- Retic Count 3%
- Peripheral Smear:
Spherocytes.
- Slide For MP: - ve
- ICT Malaria: -ve
- Coomb's Test: -ve
- Electrolytes & RFT's: Normal.

- Urine Complete: Normal
- CXR: Normal.
- USG Abdomen: Showed 14.3 cm
splenomegaly.

Investigations

- Dengue IgM: + Ve
- Planned For Osmotic Fragility Test as an out patient, once patient had recovered from acute viral illness as discussed with Dr. Abdul Hayee.

DIAGNOSIS

- Hemolytic Anemia secondary to Hereditary Spherocytosis with Dengue Fever.

Treatment

- Admission In SD – ICU
- I/V Fluids
- Anti Pyretics
- I/ V Gravinate
- I/ V Risek
- Blood Transfusions 2

Discharge

- Patient was discharged on 11th Nov 2008.

- At time of discharge she was:
 1. Afebrile
 2. Hb: 8.4 g/ dL
 3. TLC : 3.9
 4. Platelets: 160

- Advised OSMOTIC FRAGILITY TEST and follow up in the OPD after two weeks time.



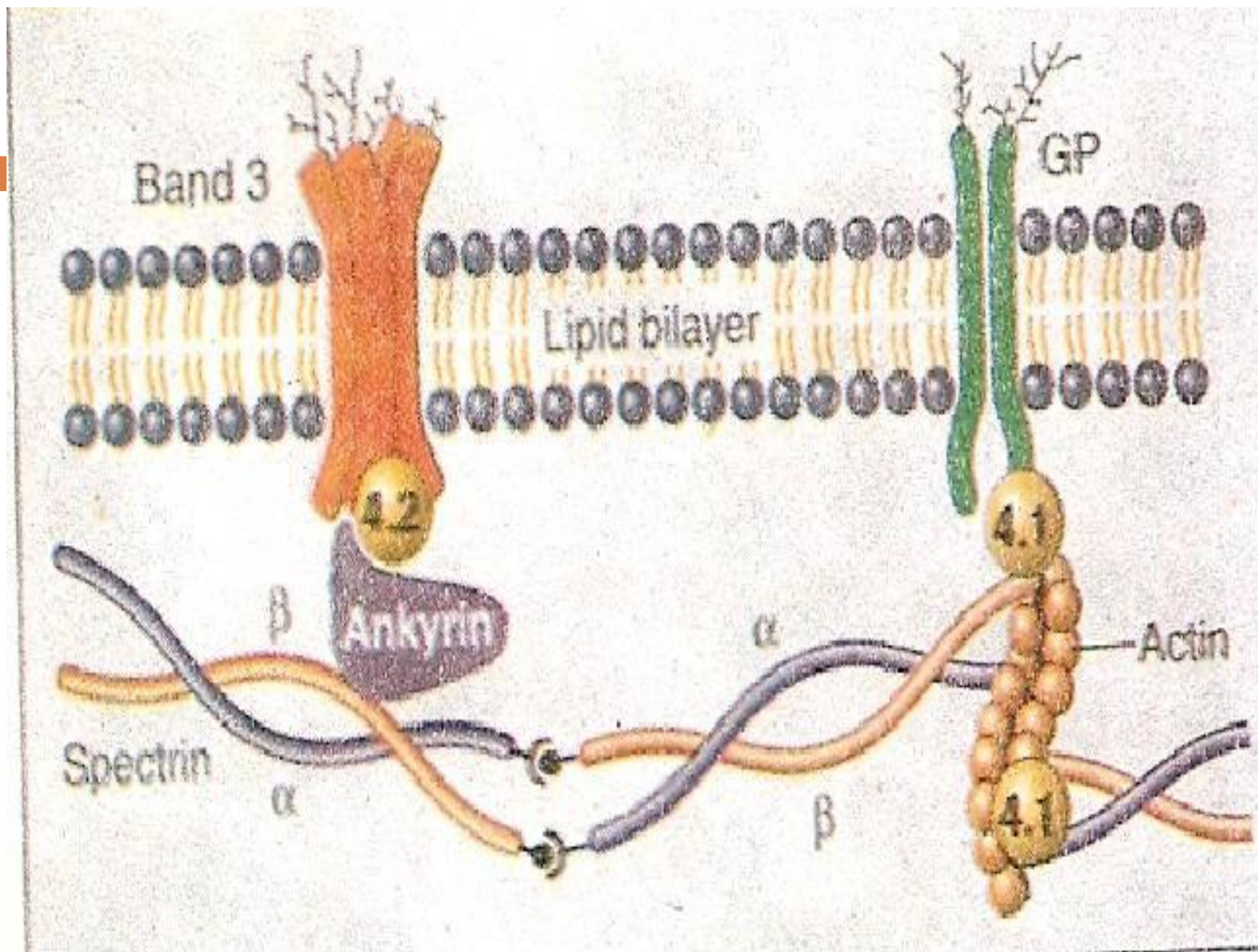
Hereditary Spherocytosis

Introduction

- This is an inherited autosomal dominant disorder characterized by an intrinsic defect in the red cell membrane that renders erythrocytes:
 1. Spheroidal
 2. Less deformable and
 3. Vulnerable to splenic sequestration and destruction.

Pathophysiology

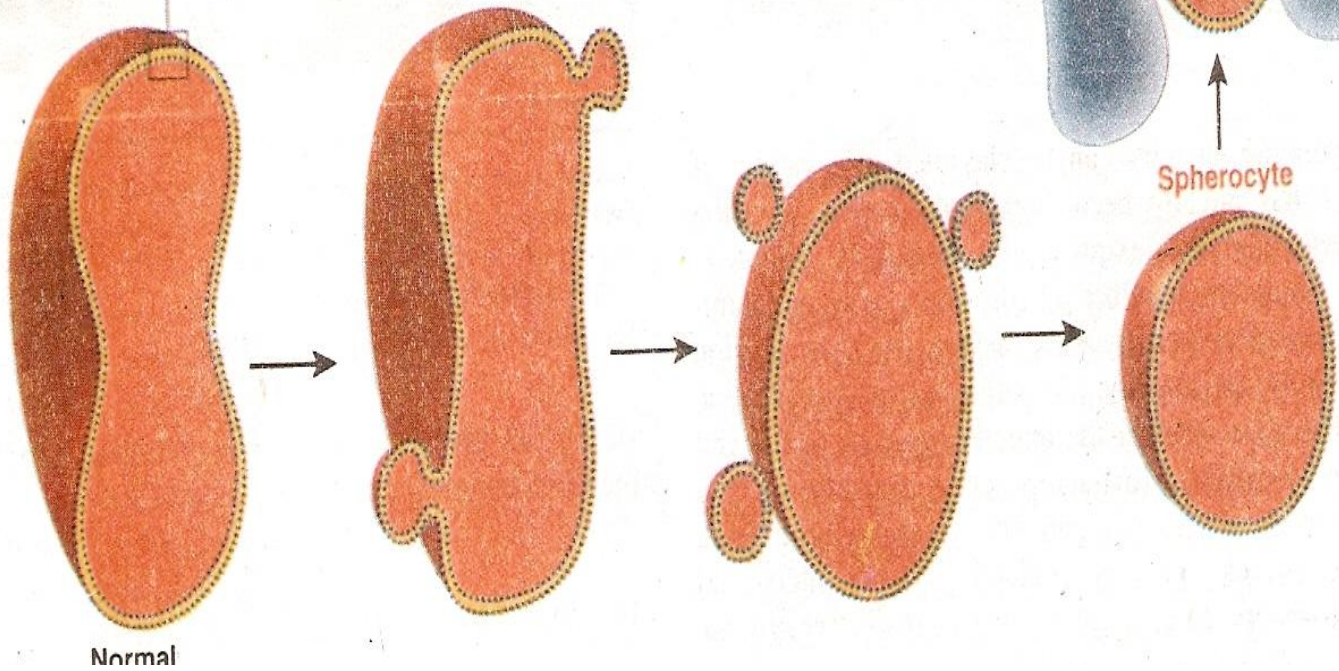
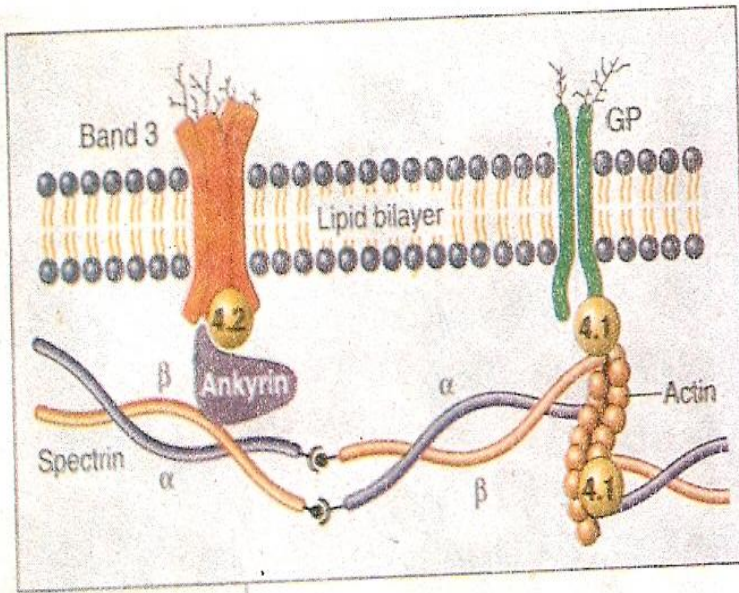
- Spectrin which is the major protein of the cytoskeleton, tethered to cell membrane by ankyrin and protein 4.1.
- Together these proteins maintain normal shape, strength and flexibility of RBC membrane.



Pathophysiology



Deficiency of spectrin, ankyrin and other proteins make RBC spheroidal, less deformable and leads to splenic entrapment and premature demise due to extravascular hemolysis



Splenic macrophage

Spherocyte

Normal

Statistics

- HS is the most common hereditary hemolytic anemia among people of Northern European .
- The incidence of the disorder is approximately 1 in 5000 people
- HS usually is transmitted as an autosomal dominant trait in 75% and 25% of all HS is autosomal recessive

Clinical Features

- Anemia, jaundice, and splenomegaly are the clinical features of HS.
- Anemia usually is mild to moderate; however, sometimes very severe.
- Jaundice is likely to be most prominent in newborns.
- Splenomegaly is the rule, and palpable spleens have been detected in more than 75% of affected subjects.
- A family history of HS is present, or the patient may report a history of a family member having had a splenectomy or cholecystectomy before the fourth decade of life.

Variants

- Mild HS occurs in 20-30% of cases of autosomal dominant HS. Anemia generally is not present because the bone marrow is able to fully compensate for destruction of red cells. Little or no splenomegaly occurs. These patients usually are asymptomatic.
- Moderate HS accounts for 60-75% of all HS cases. It is associated with mild-to-moderate anemia, modest splenomegaly, and intermittent jaundice.

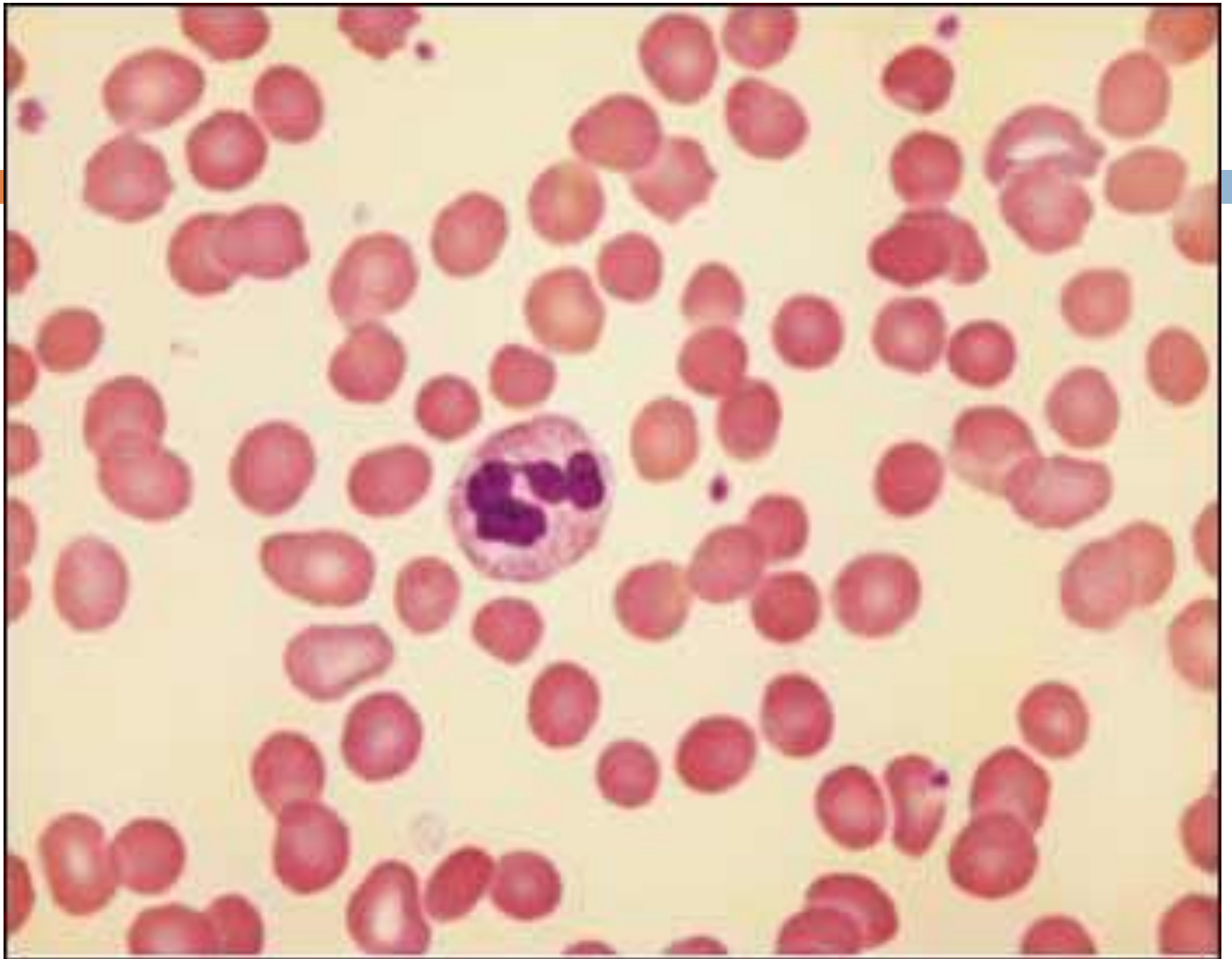
- **Severe HS the pattern of inheritance is recessive occurs in approximately 5% of all patients with HS.**
- **Severe hemolytic crisis that requires red cell transfusions and an incomplete response to treatment characterize severe HS.**
- **Aplastic crisis triggered by parvovirus infection of precursor marrow cells**

DIFFERENTIALS

1. Thalassaemia
2. G-6-P-D deficiency anemia
3. Sickle cell anemia
4. Auto immune hemolytic anemia
5. Hereditary elliptocytosis
6. Pyruvate kinase deficiency
7. Chronic Malaria

Lab Studies

- The classic laboratory features of HS include:
 1. Low Hb to variable degree
 2. An increased mean corpuscular hemoglobin concentration (MCHC) >36g/dl
 3. Reticulocytosis
 4. Unconjugated hyperbilirubinemia
 5. Increased S/LDH
 6. Splenomegaly on USG
 7. Spherocytes on the peripheral blood smear



□ OSMOTIC FRAGILITY TEST:

Useful test done by placing RBC in solution of increased hypotonicity RBC imbibe water swells and lyse earlier than normal RBC

COOMBS' TEST:

Done to distinguish from autoimmune hemolytic anemia

EKTACYTOMETRY:

Done to distinguish from elliptocytosis



TREATMENT

Medical Care

- For practical purposes, the treatment of HS involves
 1. Pre-splenectomy care
 2. splenectomy
 3. Post-splenectomy complications.

- Neonates with severe hyperbilirubinemia caused by HS are at risk for kernicterus, and these infants should be treated with phototherapy or exchange transfusions
- Uninterrupted folic acid supplementation
- Splenectomy usually is curative, except in the unusual autosomal recessive variant of HS.

Surgical Care

- Children who are candidates for splenectomy include those with severe HS requiring red cell transfusions and those with moderate HS who manifest growth failure or other signs and symptoms of anemia.
- Splenectomy for children with HS should be performed when the child is older than 6 years.
- Another interesting approach has been the use of partial splenectomy to retain splenic immunologic function while at the same time reducing the rate of hemolysis.

Complications

- Iron overload can become a serious problem due to repeated blood transfusions, resulting in hemochromatosis
- Splenectomy renders patients to life-long increased risks of infections
- Pneumococcal, meningococcal, influenza vaccine and prophylactic penicillin reduces the risk.

Prognosis

- After splenectomy, RBC survival improves dramatically, enabling most patients with HS to maintain a normal hemoglobin level.



THANK YOU